

## Purpose:

The Radiological Physics Center (RPC) reviews patient records on brachytherapy cervix trials for completeness, consistency with the protocol and dosimetric accuracy to minimize patient dose delivery and reporting uncertainty for NCI funded clinical trials. Within cervical protocols, bladder and rectum doses are specified to limit toxicity to these normal tissues. However, bladder and rectal doses reported by institutions often disagree with the RPC's calculated doses. The RPC has investigated the sources of these disagreements.

## Methods and Materials:

The RPC reviewed 182 HDR brachytherapy (tandem and ovoids (T&O)/tandem and ring (T&R)) implants and compared the institution's bladder and rectum point locations and doses to those determined by the RPC strictly adhering to protocol specifications (ICRU 38)<sup>1</sup> for point location and using its independent dose calculation algorithm. The RPC also analyzed its own uncertainty in defining these two points. A  $\pm 15\%$  dose agreement criterion was used as agreed upon between the RPC and trial groups.

## ICRU – 38 Definitions

### Bladder Reference Point

A Foley catheter is used. The balloon must be filled with 7 cm<sup>3</sup> of radio-opaque fluid. The catheter is pulled downwards to bring the balloon against the urethra. On the lateral radiograph, the reference point is obtained on an anterior-posterior line drawn through the center of the balloon. The reference point is taken on this line at the posterior surface of the balloon. On the AP radiograph the reference point is taken at the center of the balloon.

Description of ICRU Bladder/Rectum Reference

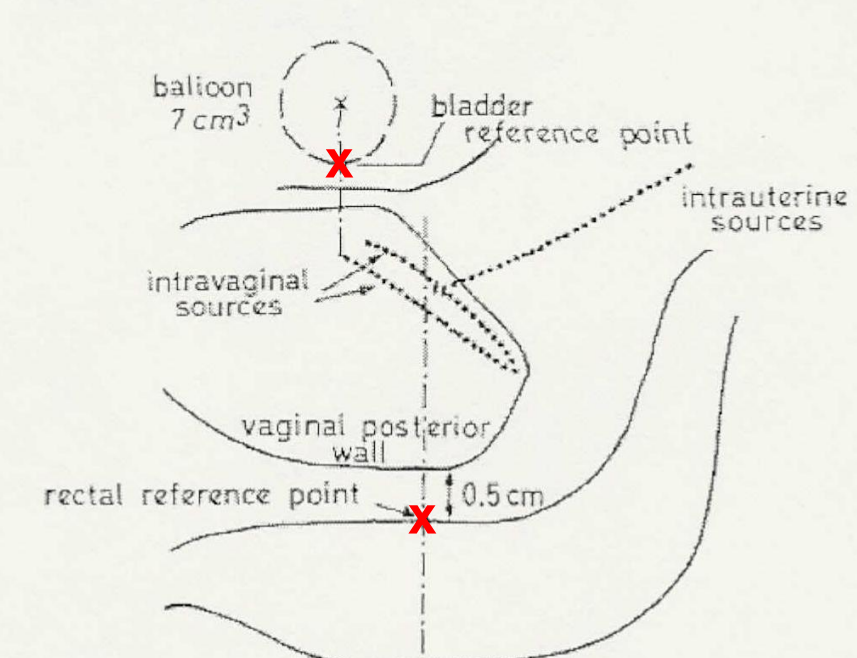


Fig. 2.2. Determination of the reference points for bladder and rectum (see text).

### Rectal Reference Point

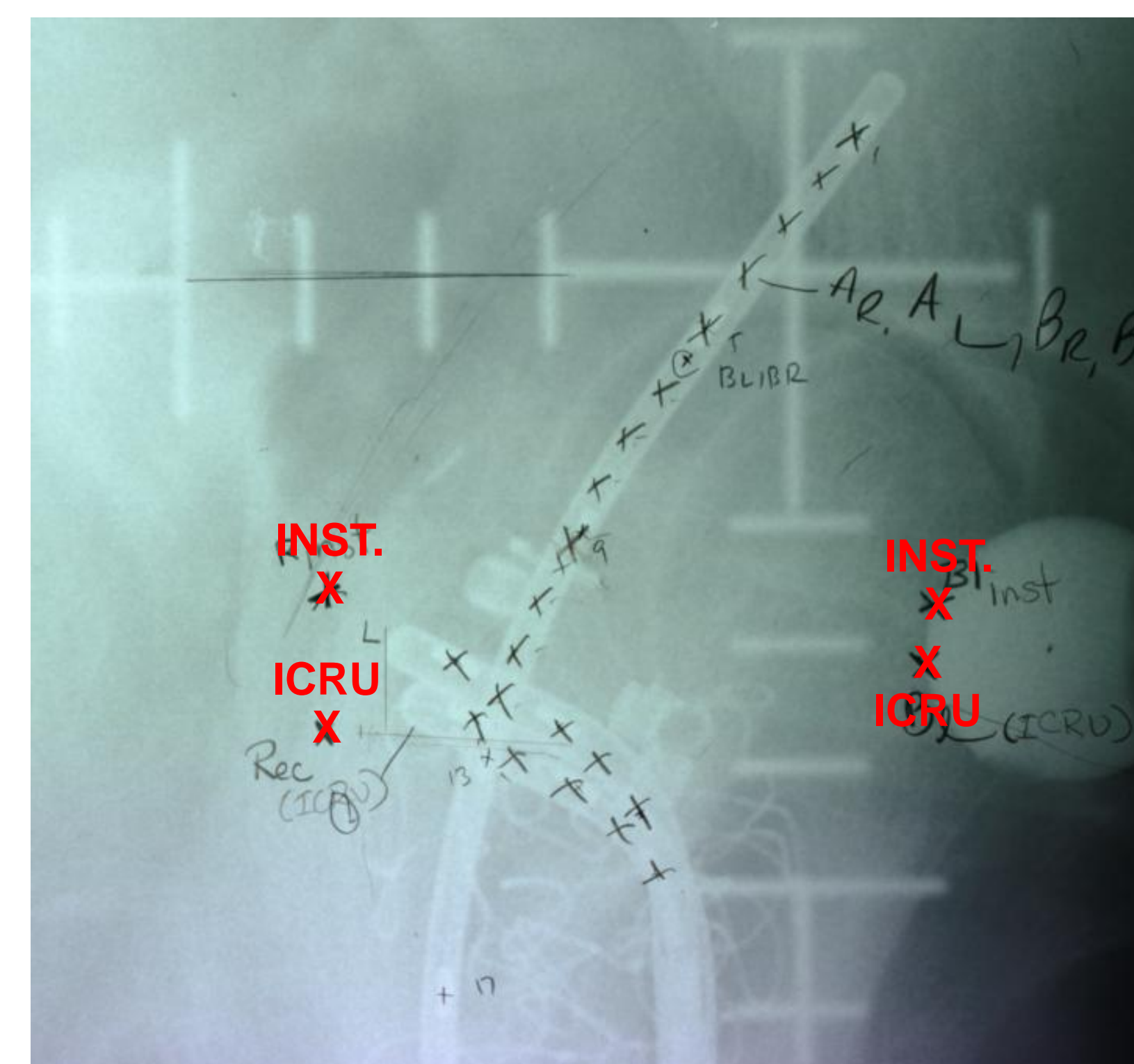
On the lateral radiograph, an anteroposterior line is drawn from the inferior end of the intrauterine sources (or from the middle of the intravaginal sources). The point is located on this line 5 mm behind the posterior vaginal wall. The posterior vaginal wall is visualized, depending upon the technique, by means of an intravaginal mould or by opacification of the vaginal cavity with a radio-opaque gauze used for the packing. On the AP radiograph, this reference point is at the inferior end of the intrauterine sources or at the middle of the intravaginal source(s).

## Results:

The RPC disagreed with the bladder and rectal doses in 25% and 45%, respectively, of the 182 implants. The RPC's own uncertainty, as determined by RPC inter-dosimetrists definitions, in defining the bladder and rectal points was 1mm  $\pm$  0.1(STDEV), respectively which in a worst case scenario might account for 7% of the dose disagreement. However, the majority of the dose disagreements were due to the institution's incorrect localization of the bladder and rectal points, by greater than 5mm and 4mm on average, respectively, away from the ICRU 38 defined location. There were no differences noted whether the applicator used was a T&O or T&R.

Table 1: The percent of implants that were reviewed by the RPC that had a point outside the 15% criterion.

Point of Calculation	Tandem & Ovoid	Tandem & Ring
Bladder	25% (119 Implants Reviewed)	24% (74 Implants Reviewed)
Rectum	41% (112 Implants Reviewed)	49% (70 Implants Reviewed)

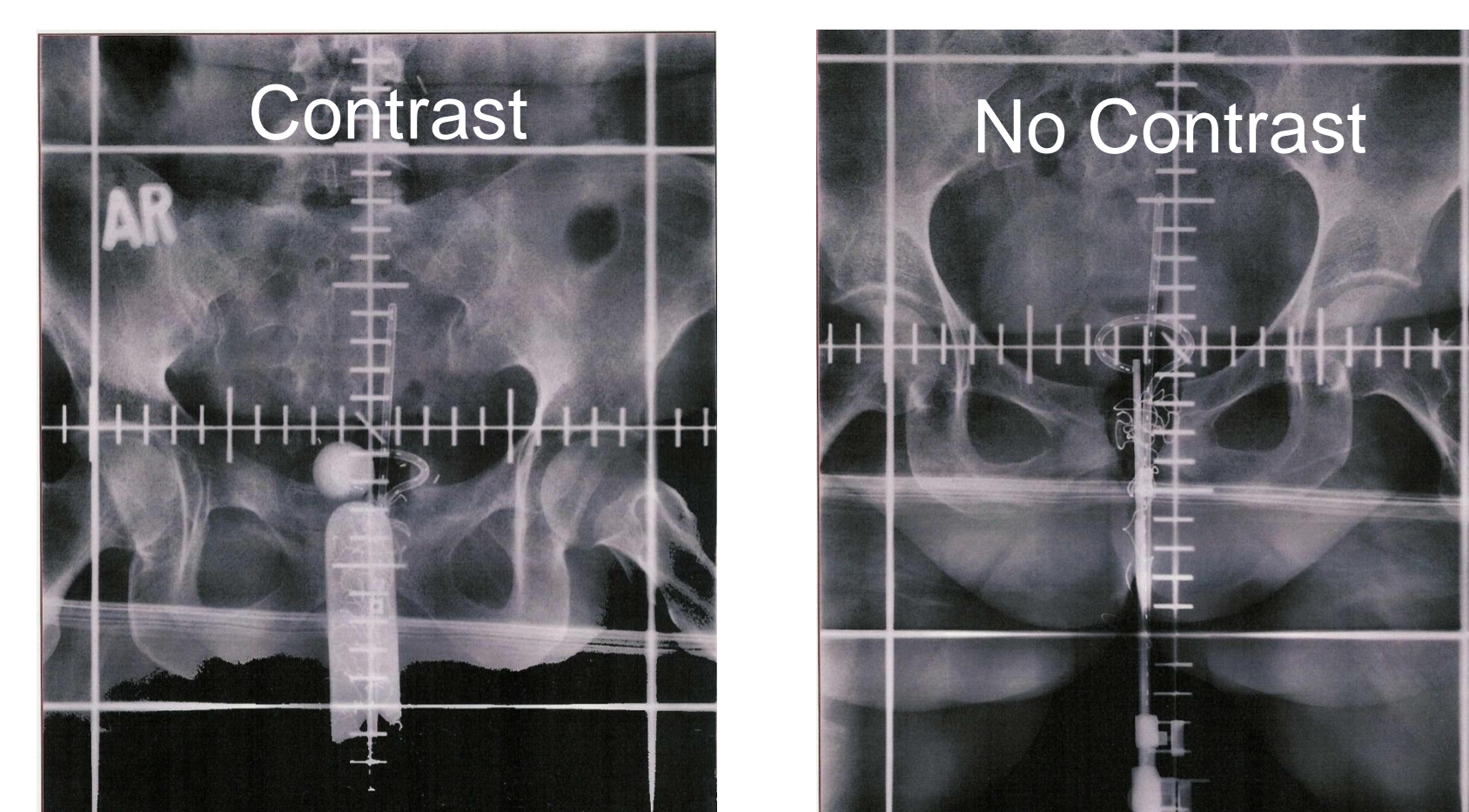


The above is an example of how different an institutions bladder and rectal points can be to the ICRU-38 definition.

### Common dosimetric errors for each point of calculation

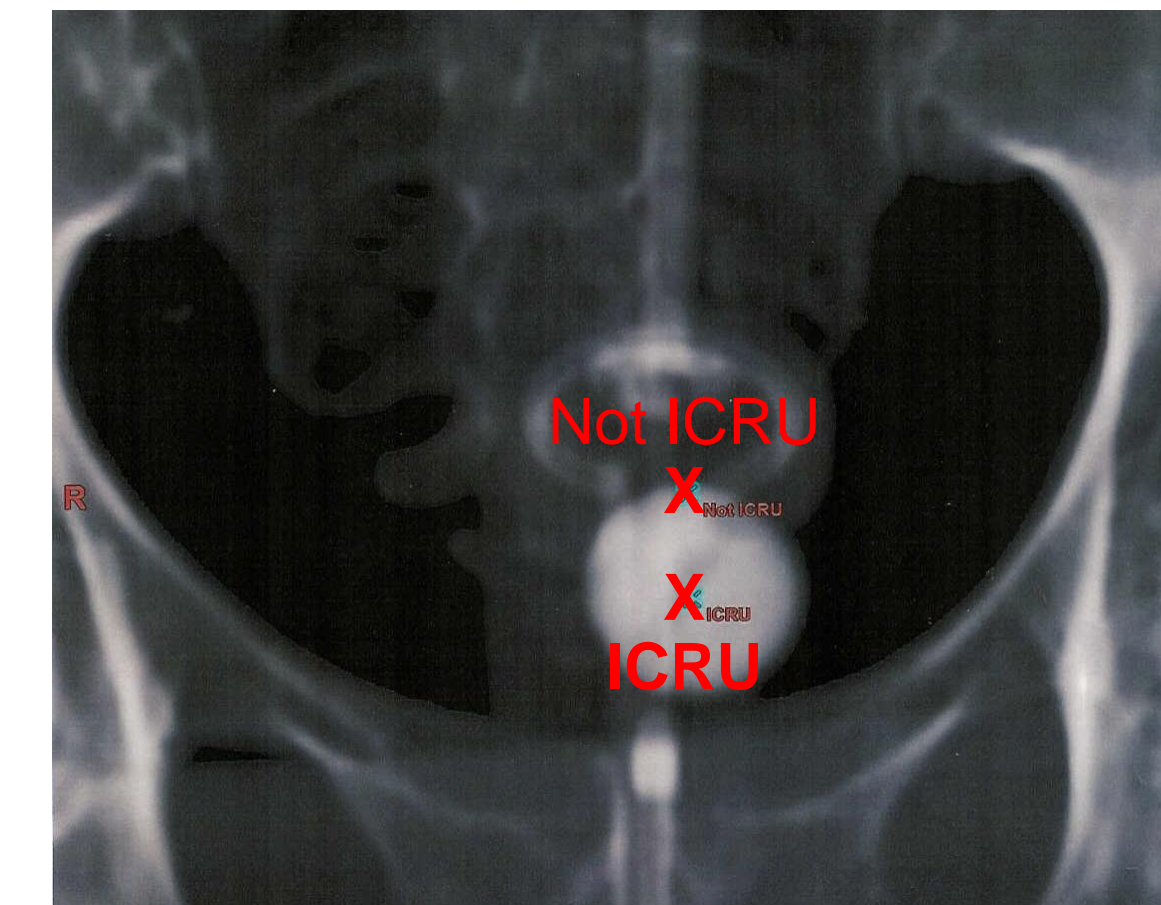
#### Bladder Point:

- Contrast was not used, therefore the RPC could not locate the bladder.

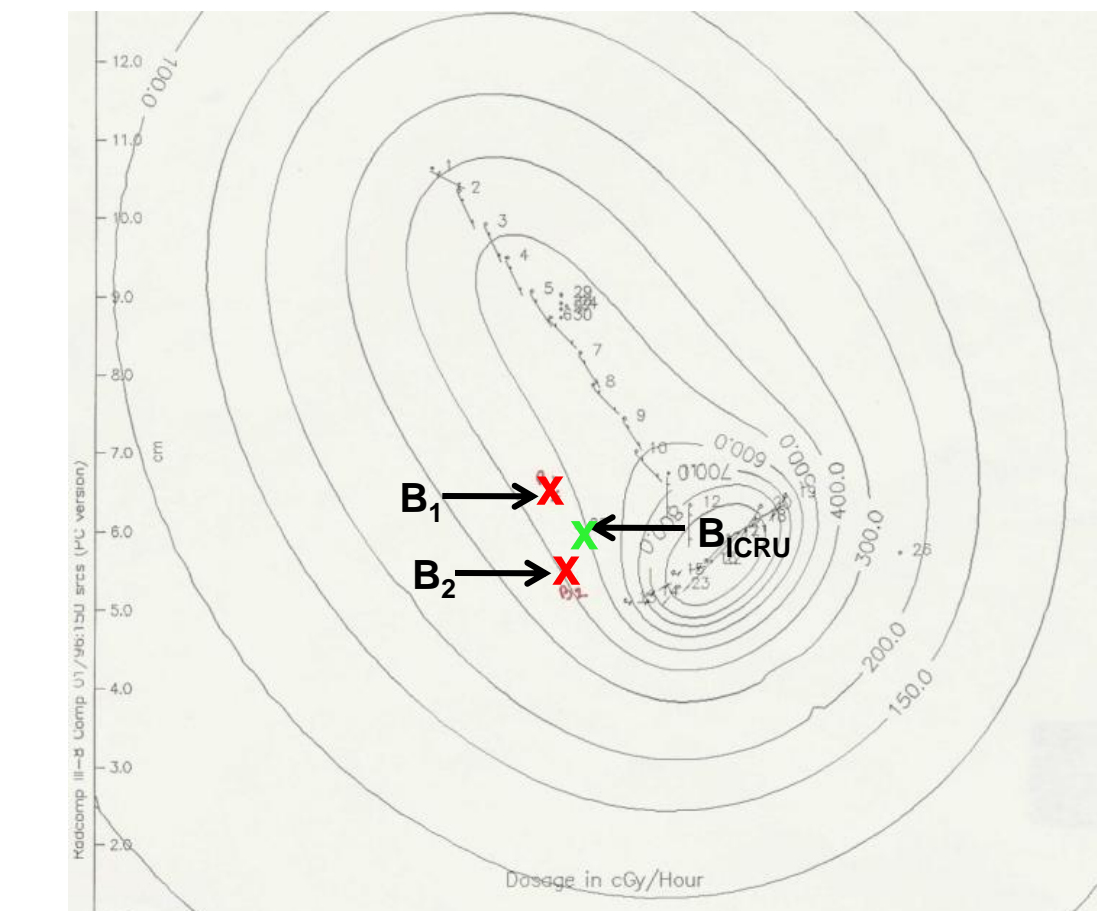


## Results continued:

- On the AP view the bladder point was not placed at the center of the bladder.

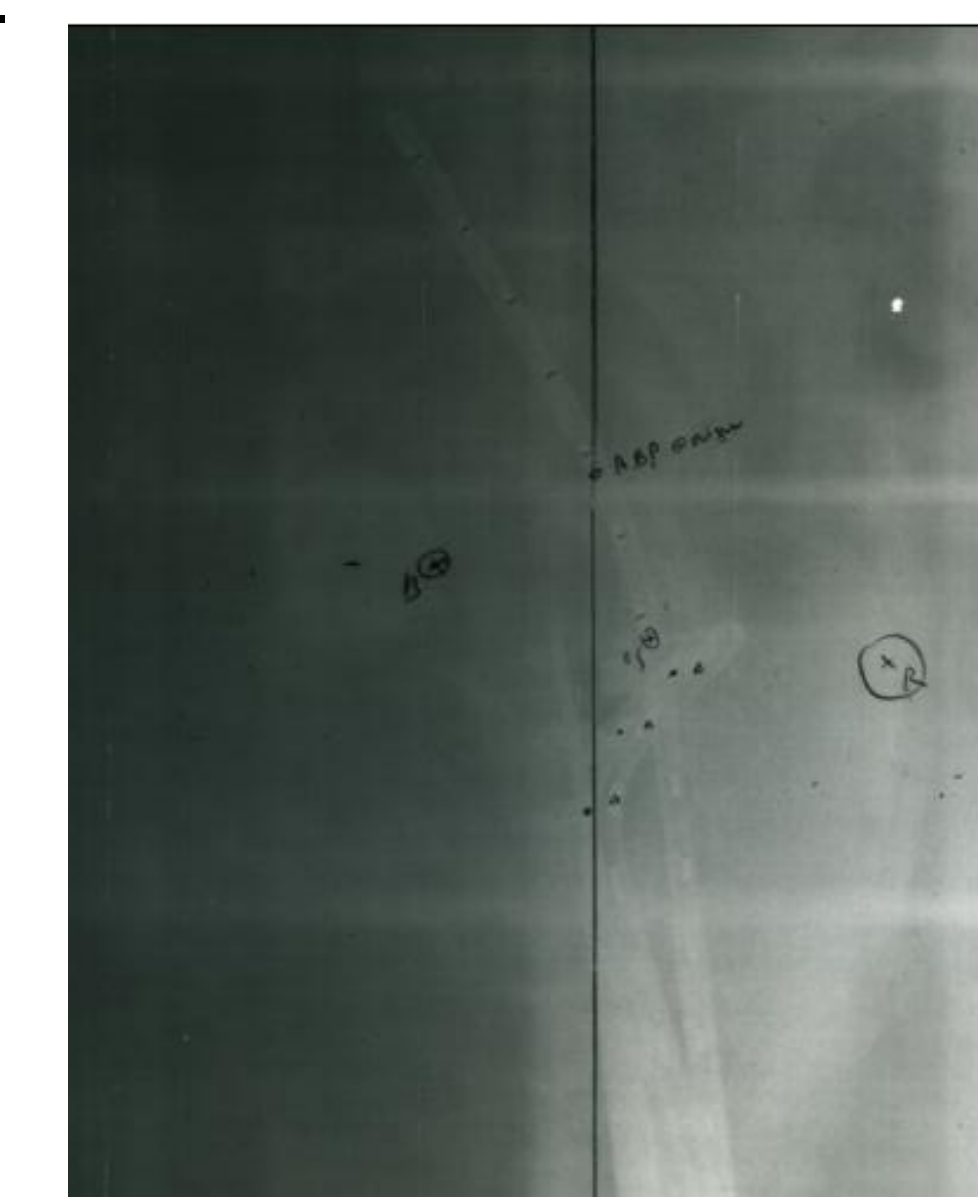


- On the lateral view the bladder point was not placed on the midpoint of the bladder wall proximal to the implant.

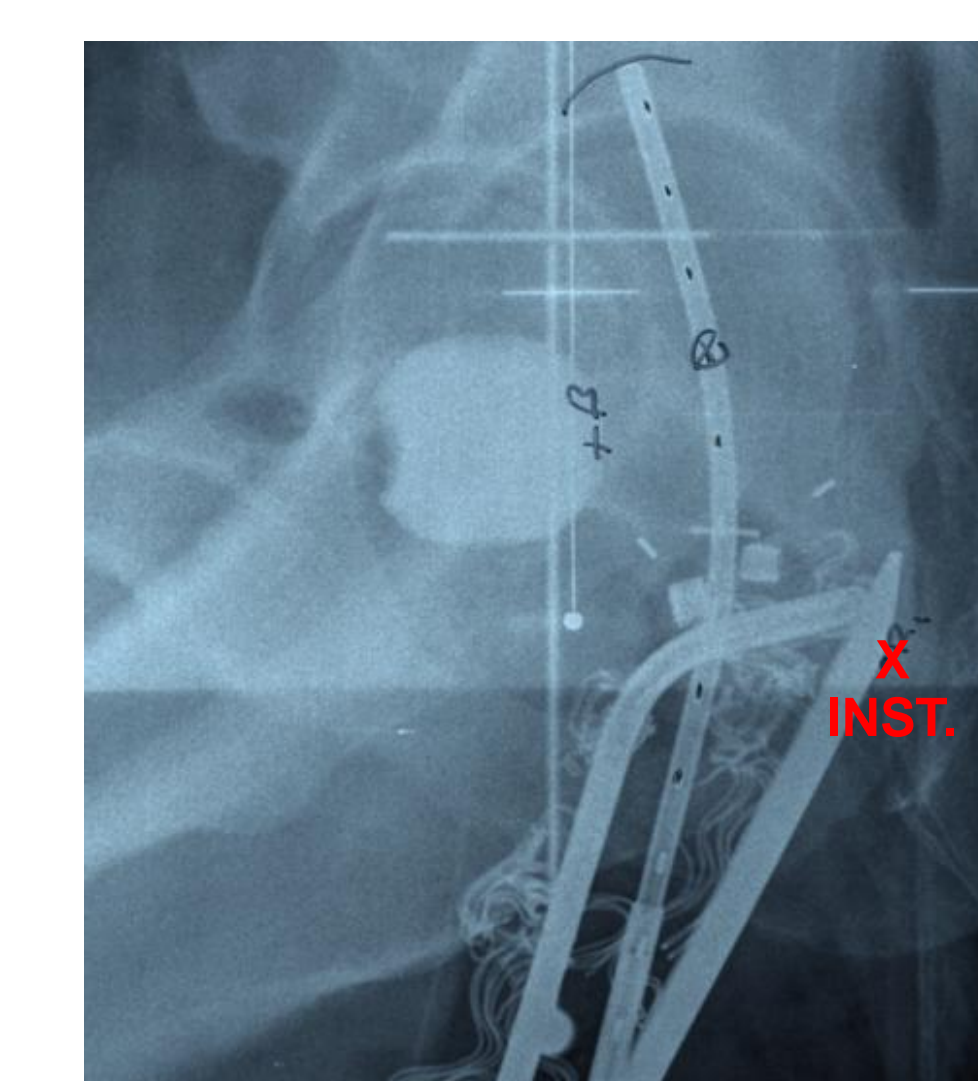


#### Rectal point:

- Radio-opaque gauze, or other vaginal contrast, was not used.

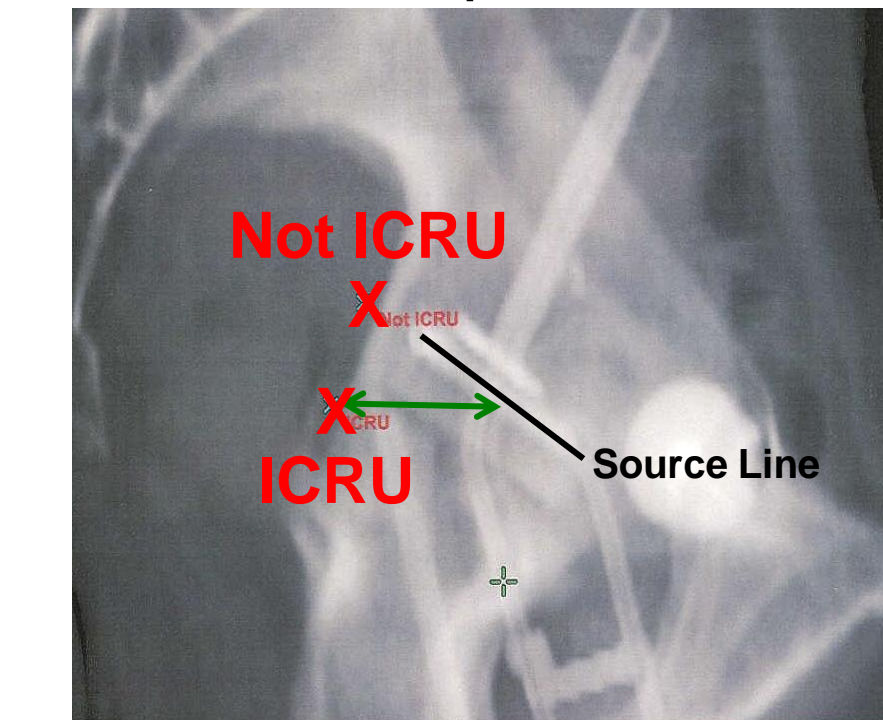


- The institution's own rectal markers or contrast were used to determine the rectal point instead of using the ICRU definition.



## Results continued:

- A distance other than 5 mm from the vaginal wall was used to define the rectal point.

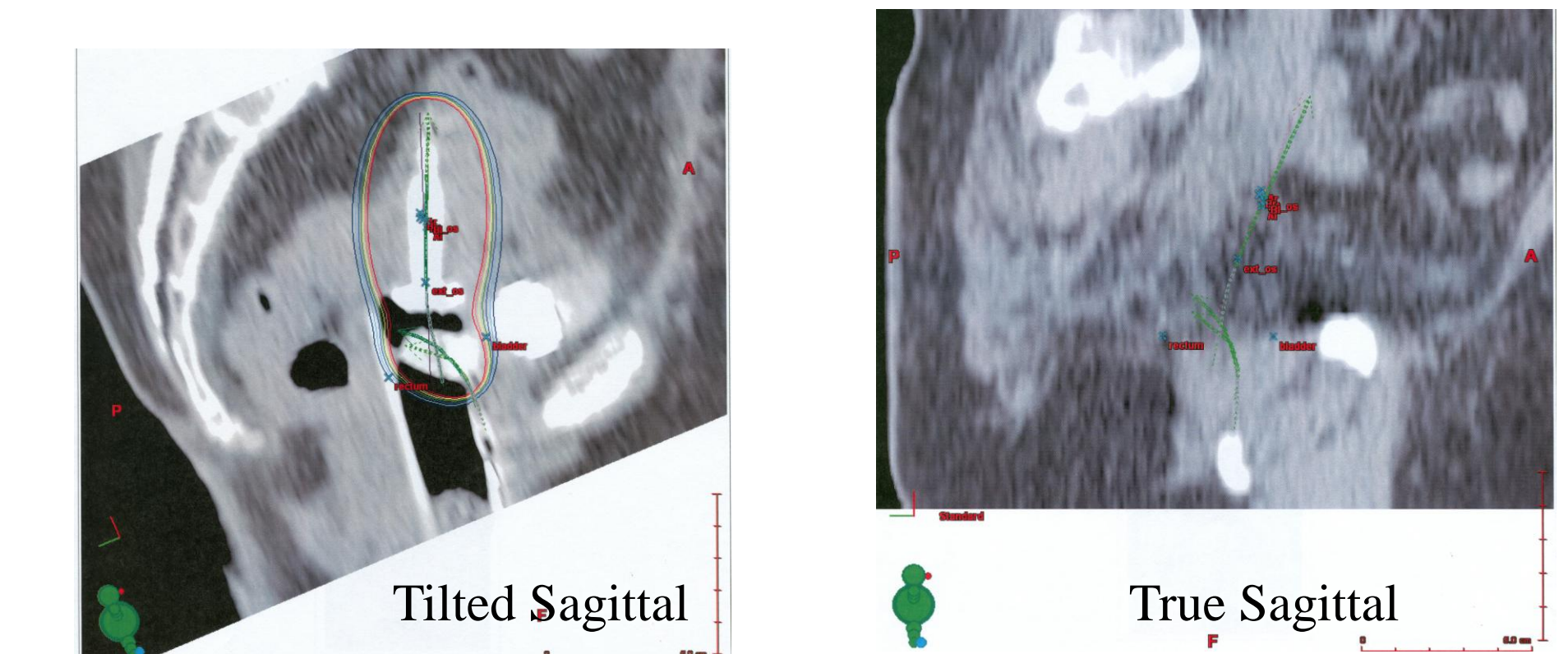


### Common dosimetric errors made with CT image based planning

To view the sources, the CT images need to be aligned by tilting the patient axis. Before defining the ICRU rectal and bladder points the tilt must be returned to a true coronal and sagittal view.

#### Rectum:

- The rectal point is determined on a true sagittal view. By leaving the image tilted the rectal point is located in an incorrect plane.



#### Bladder:

- The center of the bladder is determined on a true sagittal view. By leaving the image tilted the bladder point is located in an incorrect plane.

## Conclusions:

Most dose reporting errors resulted from institutions incorrectly defining the bladder and rectum dose calculation points as defined by ICRU 38<sup>1</sup>. Additional education, increase in rapid reviews (feedback given after 1st implant), more timely reviews (feedback given before additional patients placed on study) of implant data and communication with institutions are needed to reduce the number of discrepancies. Even though the bladder and rectum points have been defined in clinical protocols, a large number of institutions still do not use these definitions to determine patient critical structure doses.

These reporting errors lead to inconsistencies in reported doses for trials that influence patient toxicity dose response results.

Participants in clinical trials should follow the protocols carefully to avoid making errors that can result in protocol deviations.

### References

<sup>1</sup>Dose and Volume Specification for Reporting Intracavitary Therapy in Gynecology, ICRU Report 38, March 1985.

### Support:

The investigation was supported by PHS grant CA10953, CA21661 awarded by the NCI, DHHS.